

## **Tuberous Sclerosis presenting as a case of Obsessive Compulsive Disorder (OCD) : a rare presentation**

*Anuj Khandelwal<sup>1</sup>*  
*Avinash De Sousa<sup>2</sup>*  
*Alka Pawar<sup>3</sup>*

<sup>1</sup> Resident Doctor

<sup>3</sup> Professor and Head

Department of Psychiatry, B.J. Medical College, Pune.

<sup>2</sup> Research Associate, Department of Psychiatry, Lokmanya Tilak Municipal Medical College, Mumbai

E-mail – drajkl@yahoo.com

---

### **ABSTRACT**

*Tuberous sclerosis is a complex neurological disorder with epilepsy, mental retardation, dermatological and neurological manifestations. Here we present a rare case where tuberous sclerosis presented as a case of obsessive compulsive disorder and the diagnosis of tuberous sclerosis was made on investigation and examination.*

**Key words:** *tuberous sclerosis, epilepsy, mental retardation, obsessive compulsive disorder, OCD.*

### **INTRODUCTION**

Tuberous Sclerosis Complex (TSC) is a genetic disorder characterized by hamartomatous growths in many organs including the heart, kidney, skin and brain [1]. The disease primarily affects the skin and the central nervous system as well as other organ systems. The diagnosis of the syndrome is essentially clinical, based on the presence of a constellation of various cutaneous and systemic changes [2]. Some of the commonly reported neuropsychiatric disorders in TSC are attention deficit hyperactivity disorder, autism spectrum disorders, aggressive outbursts, anxiety disorder, mood disorder and psychoses [3]. It is a multisystem neurocutaneous syndrome which usually present early in the first year of life with seizures and later within first ten years of life with mental retardation [4]. Our case is one where the initial presentation was with psychiatric manifestations and a diagnosis of tuberous sclerosis was made on clinical examination and based on investigations. The case is also rare due to the fact that TSC was detected later in life.

## CASE REPORT

A 30 year old married female hailing from a middle socioeconomic family background was brought by husband with complaints since 12 years prior to presentation. She developed without any apparent stressor, the urges to carry out actions repeatedly and acting repeatedly on them due to the need for order and exactness. Initially this was seen in her routine household work, but later over next 3 to 4 months the repeating rituals extended to her self care when while dressing she started with robing and disrobing self a number of times until she felt satisfied. Gradually over a year her ritualistic behaviors increased further and she began to count for five respirations before starting any work and until the work gets over she would avoid deglutition and hold saliva in her mouth. Along with this she would repeatedly go to the toilet even without an urge to urinate. She used to spend more time than usual to do her daily chores but her symptoms were less disabling initially and she used to manage everything. But gradually over next two to four years her symptoms increased in intensity and she began with total avoidance to do any work and would also not allow her children to do anything. She got totally home-bound with total avoidance to go outside due to fear of contamination. These all behaviors were associated with her magical thinking that if she does not indulge in the behaviors than her husband will meet with some misfortune. She found them distressing and unpleasant and tried different ways to distract self and suppress the thoughts, but they would nevertheless intrude into her consciousness. Looking at her distress and irritability her husband tried getting her treated by various faith-healers over extended period of 3 years. But perceiving no improvement he got burnt out and dropped expectations of her getting well, which along with the marked irritability of the patient paved path for discord in their happily married life.

During the same period the patient suffered with two generalized tonic clonic seizures in her late 20s for which she took treatment for only for a few months (Details not available). The treating doctor when came across such symptoms along with epilepsy, advised them to visit a psychiatrist for which they came to consult. On detailed pedigree charting epilepsy was found in her father and two of her younger siblings, with behavioral disturbances in one of them (details other than this were not available). On physical examination the patient was seen to have Shagreen patches (2 pebbly skin patches), Ash leaf spots (6 hypomelanotic macules) and Koenon tumors (4 unguinal fibromas). These were confirmed by referral to the skin department. Tuberous sclerosis was suspected and thus MRI scan was done which revealed a subependymal giant cell astrocytoma with small cortical lesions and periventricular calcific nodules. Neurology reference was done and tuberous sclerosis was confirmed (see images).

Her IQ score on Wechsler Adult Intelligence Scale-IV was 98 and Yales Brown Obsessive Compulsive Scale score was 34/40. On day one mental status examination (MSE), the patient was seen irritable during the interview with requesting the clinician not to ask much of questions with increased psychomotor activity and increased reaction time. Eye to eye contact was initiated but not maintained with rapport established with difficulty. Speech was non-spontaneous but relevant and coherent with increased rate and decreased volume. Affect was anxious, irritable and appropriate. She had obsessive thoughts of contamination, symmetry, ruminations, self-doubts with compulsive acts of repeating rituals, counting, avoiding and symmetry-precision. She recognized the thoughts to be her own and not implanted from somewhere else. She perceived them untrue, senseless and admitted a subjective sense of struggle resisting

the obsessions which nevertheless intrudes into her conscious awareness. Her judgment was intact and insight into the illness present.

Diagnosis of Obsessional Thoughts and Acts (F42.2) with comorbid Tuberous Sclerosis (Q85.1) was made as per ICD-10. Looking towards the disturbed family dynamics and the risk of non-compliance in future, getting fast improvement became the short term target of the treatment. Thus the patient after an informed consent about the possible risk of seizure was started on a combination Fluoxetine 20 mg per day in a morning dose and Clomipramine 50 mg a day in divided doses, which were gradually titrated over the next 4 weeks. Along with pharmacotherapy, behavior therapy in the form of exposure and response prevention was also started. From the neurology department the patient was started on sodium valproate 600 mg a day in divided doses for seizure prophylaxis.

Her Yale Brown Obsessive Compulsive Scale score decreased from 34/40 to 18/40 at the end of two months of treatment. The patient regularly followed up with us and maintained good improvement at the end of 6 months.

## DISCUSSION

This case was unique as it was a case of obsessive compulsive disorder (OCD) with silent tuberous sclerosis (TSC). Researchers have described a case of OCD but in an already diagnosed case of TSC and concluded that the manifestations of TSC can be multiple and the management of OCD in a patient with TSC remains the same [5]. Case series have also found rarity of OCD in cases with TSC. They studied a clinic population of 241 patients with TSC, with only one detected case of OCD [6]. Our case was diagnosed for the first time with TSC very late in life. This was most probably due to late onset of seizures and no mental subnormality. This is against the usual early presentation of TSC. Authors have reported that most cases of TSC manifest with seizures in the first years of life [7] while some have concluded that mental subnormality is rare without seizures, which support no mental subnormality in our case [8]. In our case though the TSC diagnosis was made late, the OCD symptoms showed a good response to pharmacotherapy and behavior therapy. TSC rarely goes undiagnosed and may present very late in life for the first time with psychiatric manifestations. Clinicians should maintain a high degree of suspicion for the possibility of hidden TSC whenever a case present with atypical findings. Comprehensive re-evaluation of atypical presentations of OCD with epilepsy and skin manifestations is particularly relevant to uncover hidden neurogenetic disorders.

## REFERENCES

1. Curatolo P, Cusmai R, Cortesi F, Chiron C, Jambaque I, Dulac O. Neuropsychiatric aspects of tuberous sclerosis. *Ann NY Acad Sci* 1991;615(1):8-16.
2. Curatolo P, Verdecchia M, Bombardieri R. Tuberous sclerosis complex: a review of neurological aspects. *Eur J Pediatr Neurol* 2002;6(1):15-23.
3. Prather P, de Vries PJ. Behavioral and cognitive aspects of tuberous sclerosis complex. *J Child Neurol* 2004;19(9):666-74.
4. Roach ES, DiMario FJ, Kandt RS, Northrup H. Tuberous sclerosis consensus conference: recommendations for diagnostic evaluation. *J Child Neurol* 1999;14(6):401-7.
5. Bhattacharya A, Das S, Nath K, Dutta D, Saddichha S. Atypical presentation of tuberous sclerosis and obsessive compulsive disorder in an adult male. *Ann Indian Acad Neurol* 2012;15:161-2.
6. Muzykewicz DA, Newberry P, Danforth N, Halpern EF, Thiele EA. Psychiatric comorbid conditions in a clinic population of 241 patients with tuberous sclerosis complex. *Epilepsy Behav* 2007;11:506-13.
7. Osbourne JP. Diagnosis of tuberous sclerosis complex. *Arch Dis Child* 1988;63:1423-5.

8. Pampiglione G, Pugh E, Infantile spasms and subsequent appearance of tuberous sclerosis syndrome. *Lancet* 1975;2:1046.

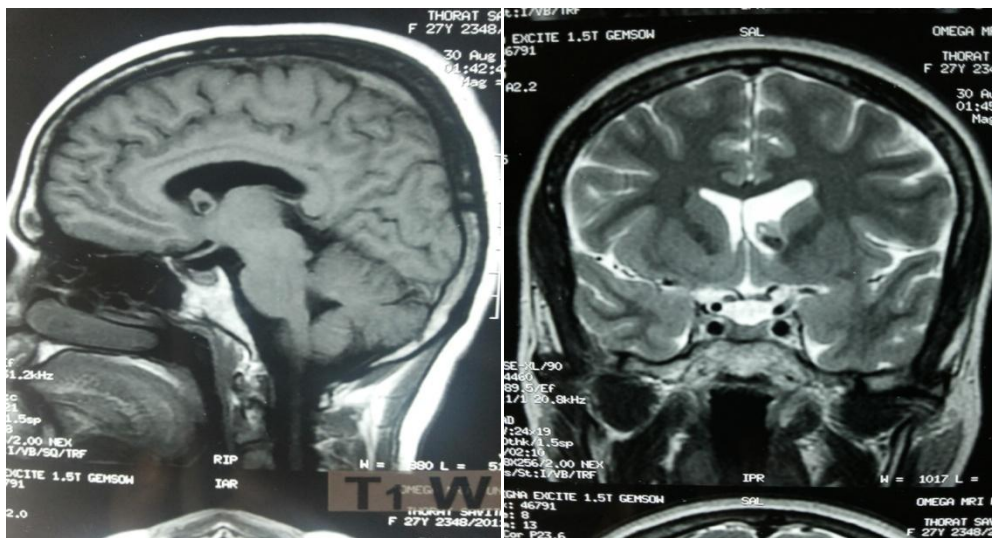
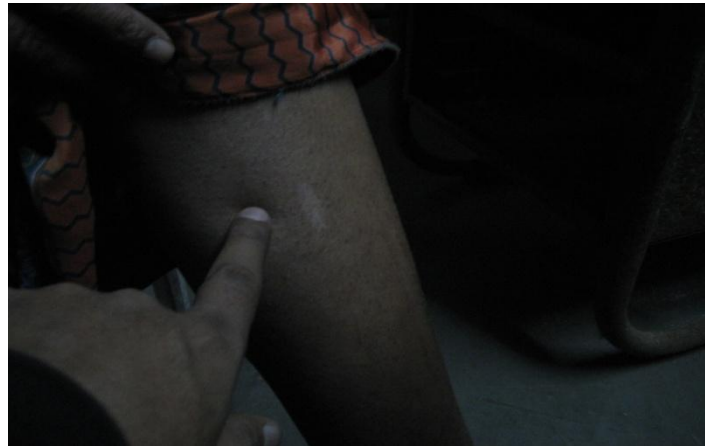Acknowledgements – Nil

Conflict of Interest – Nil

Funding – Nil

### Images – Lesions of the patients confirming a diagnosis of Tuberous sclerosis

#### Ashleaf-Chagasin spots



**MRI showing subependymal giant cell astrocytoma (left) and small cortical lesions (right)**