

## The Thalamus

*Sagar Karia*<sup>1</sup>

<sup>1</sup>Specialty Medical Officer, Department of Psychiatry, Lokmanya Tilak Municipal Medical College, Mumbai.

E-mail – kariabhai117@gmail.com

---

### INTRODUCTION

- Word Thalamus from Greek origin meaning “inner room” or “chamber”.
- Is an egg shaped mass of grey matter forming part of Diencephalon and forming lateral wall of 3<sup>rd</sup> ventricle.
- Narrow anterior end is directed medially while broad posterior end is directed laterally. Its long axis is 30° oblique to midline.
- Size is 3.5cm x 1.5cm.
- Covering its lateral surface is the external medullary lamina consisting of thalamocortical and corticothalamic fibres.
- Internal medullary lamina consists mainly of internuclear thalamic connections. It is 'Y' shaped and divides thalamus into 3 different nuclear masses.

### Thalamic Nuclei

- **Anterior Group:** portion between diverse limbs of 'Y'. It contains Anterior nuclei.
- **Medial Group:** part of thalamus lying on medial side of stem of 'Y'. It contains intralaminar nuclei, centromedian nuclei, medial nuclei and midline nuclei.
- **Lateral Group:** part lying on lateral side of stem of 'Y'. It is divided into 2 groups- ventral group and dorsal group.
  - **Ventral** group contains ventroanterior, venterolateral, and venteroposterior nuclei and most posteriorly medial and lateral geniculate bodies. Venteroposterior nuclei is divided into venteroposteriorlateral and venteroposteriormedial nuclei.
  - **Dorsal** group contains pulvinar, lateral posterior and lateral dorsal nuclei.

## Connections of the Thalamus

Functionally divided into extrinsic and intrinsic nuclei.

**Extrinsic nuclei** are cortical relay nuclei and receive afferent fibres from extrathalamic sources. Axons of these cells are distributed to primary cortical areas- pre and post central cortices, visual and auditory cortical areas.

Different extrinsic nuclei are:

- a) **Posteroventral nucleus:** receives medial lemniscus and trigeminal lemniscus.

**Medial lemniscus** carries afferent from gracile and cuneate nuclei and afferent fibres from ventral and dorsal spinothalamic tracts. Thus impulses from touch, pressure, temperature and pain receptors synapse in these nuclei. Except pain they are relayed to posterior central cortex.

**Trigeminal lemniscus** carries same afferents from face with taste fibres. Muscle afferents from limbs which synapse in posteroventral nucleus are relayed into area 3a of cortex.

- b) **Lateroventral nucleus:** receives dentatothalamic fibres from cerebellum carrying proprioceptive information and projecting to precentral motor cortex- area 4 and 6.
- c) **Anterior nucleus:** receives mamillothalamic tract which carries impulse relayed in mamillary body from hippocampus. Sends impulses to cingulate gyrus.
- d) **Medial geniculate body:** receives projection from auditory fibres from cochlear nuclei and inferior colliculi which relay to auditory cortex.
- e) **Lateral geniculate body:** receives from primary visual neurons and project to calcarine cortex.

**Intrinsic Nuclei** receive fibres from other structures in thalamus. Formed of midline, intralaminar, dorsomedial and dorsolateral nuclei and pulvinar nuclei.

- a) **Dorsomedial and intralaminar nuclei** - connections with frontal lobes and hypothalamus.
- b) **Midline and intralaminar nuclei** project to neostriatum.
- c) **Pulvinar** project to inferior parietal lobes.
- d) **Dorsomedial** receives and project to precuneate gyrus.
- e) **Reticular nucleus** lies between internal capsule and external medullary lamina, receives fibres from all intralaminar nuclei, which are sites of synapse of afferent tracts of ascending reticular formation and impulses relayed to cortex forming part of Reticular Activating System(RAS).

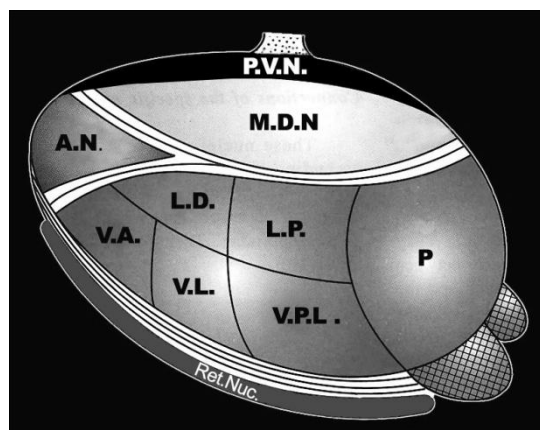
### Functions of the Thalamus

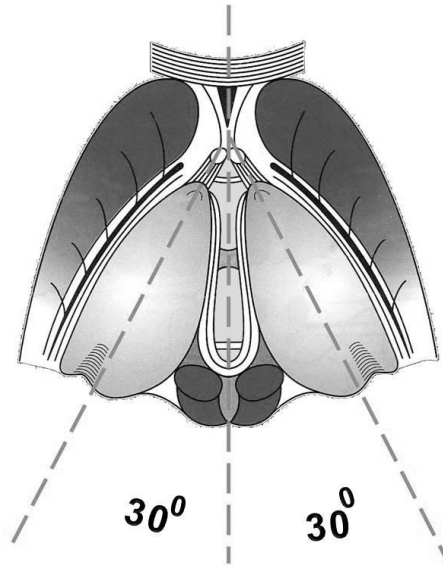
- a) Sensory integration and relay station of all sensory pathways except olfactory.
- b) Capable of recognition of pain, thermal and some tactile sensations.
- c) Influences voluntary movements by receiving impulses from basal ganglia and cerebellum and relaying to motor cortex.
- d) Through Ascending Reticular Activating System helps in maintaining state of wakefulness and alertness.
- e) Receive impulses from hypothalamus and project to cingulate gyrus and prefrontal cortex - participates in affective reactions- determination of mood.
- f) Role in recent memories and emotions.
- g) Influences electrical activities of cerebral cortex i.e. Role in synchronisation and desynchronisation of EEG waves.

### Clinical correlations

- a) **Thalamic syndrome:** thrombosis of artery supplying venteroposterior nucleus. Threshold for pain, touch and temperature is decreased on opposite side (thalamic overreaction). When threshold is reached, sensations are exaggerated, perverted and disagreeable. For e.g. Pinprick is felt as severe burning sensation, even music is disagreeable, light touch causes excruciating pain, patient may have emotional instability with spontaneous laughing and crying.
- b) **Thalamic Hand:** Hand on opposite site of lesion is held in abnormal posture- forearm is pronated, wrist flexed, metacarpo-phalangeal joint and interphalangeal joint extended. Fingers can be moved but slowly.
- c) Impairment of sensory perceptions on opposite side.
- d) Anterior nucleus needed for attention and recent memory so any pathology lead to loss of recent memory.
- e) Cognitive deficits, poor verbal fluency and apathy
- f) Relation with etiology of schizophrenia as glutamate abnormalities found in projection fibres from thalamus to cortex.
- g) Also plays a role in obsessive compulsive disorder and late life depression.

### DIFFERENT NUCLEI OF THE THALAMUS





**THALAMUS BEING DIVIDED BY INTERNAL MEDULLARY LAMINA**

**SUGGESTED FURTHER READING**

1. Physiology: Prep Manual for Undergraduates. By Vijaya D. Joshi, Sadhana Joshi Mendhurwar.
2. Textbook of Clinical Neuroanatomy by Vishram Singh. 2<sup>nd</sup> Edition.